

Visual Outcome and Complications in Ab-Externo Scleral Fixation IOL in Aphakia

Azizur Rahman, Israr Ahmed Bhutto, Sadia Bukhari, Mazharul Hassan, Muhammad Nasir Bhatti

Pak J Ophthalmol 2011, Vol. 27 No. 2

See end of article for authors affiliations

Correspondence to:
Azizur Rahman
Isra Postgraduate Institute of Ophthalmology,
Al-Ibrahim Eye Hospital
Old Thaana, Malir, Karachi

Submission of paper
January' 2011

Acceptance for publication
May' 2011

Purpose: To assess the visual outcome and complications in patients after Ab-externo scleral fixation of intraocular lens.

Materials and Methods. This quasi experimental study was conducted at Isra Postgraduate Institute of Ophthalmology, Al-Ibrahim Eye Hospital, Malir, Karachi; from May 2006 to April 2007. Study included total 30 eyes of 30 patients fulfilling criteria. All cases were worked up according to the protocol. All patients underwent Ab-externo scleral fixation of IOL.

Patients were followed up at 1st day, 1st week, 1st month, 2nd month and 3rd month. Complete eye examination including best-corrected visual acuity and complications were noted on each visit.

Results: Best corrected visual acuity improved in 29 (96.7%) patients while 26 (86.7%) patients showed BCVA 6/12 or better. The most common intraoperative and postoperative complications observed were vitreous hemorrhage and astigmatism respectively.

Conclusion: Ab-externo scleral fixation of an IOL was found to be safe and showed favourable postoperative results.

Intraocular lens (IOL) implantation to correct the aphakia offers superior visual rehabilitation in comparison to aphakic spectacles or contact lens. In the absence of capsular support; anterior chamber lenses, iris fixated lenses and scleral fixated intraocular lenses may be considered.^{1,2} Placement of IOL in the posterior chamber rather than anterior or iris fixated lenses reduces the risk of various complications, like keratopathy, damage to anterior chamber angle structure, pupillary block glaucoma, hyphema, uveitis, iris chafing, dislocation and pseudophakodonesis.^{1,4} Additionally, positioning lens closer to the rotational center of the eye, just anterior to the vitreous face, may reduce the centrifugal forces on the lens and stabilize the ocular contents, thereby decreasing the probability of complications such as iritis, cystoids macular edema (CME) and retinal detachment.^{3,5} Another advantage of positioning the lens closer to the nodal point and center of the eyes is the superior optical properties of the lens in this position.^{3,6}

There are two surgical techniques, namely Ab-interno (inside out) and Ab-externo (outside in). The Ab-interno technique involves the passage of needle from the inside of the eye to the outside through the sclera.^{3,4,7,8} The Ab-externo technique involves the passage of a needle from the outside of the eye to the inside through the sclera.³ In the Ab-externo method; scleral fixation of IOL exactly in the ciliary sulcus can be achieved^{4,9}. With this method, the surgeon's view is never obscured. All the manipulation occurs in the iris plane. The surgeon can thus decrease the risk of vitreous hemorrhage. Retinal detachment and lens malposition by avoiding the potential inaccuracies of suture placement those are inherent to the Ab-interno technique^{3,10-13}.

MATERIAL AND METHOD

The study included 30 eyes of 30 consecutive patients who underwent Ab-externo scleral fixation of IOL during May 2006 to April 2007 at Isra Postgraduate

Institute of Ophthalmology, Al-Ibrahim Eye Hospital, Karachi. Patients were selected from the general OPD and cataract clinic of Al-Ibrahim Eye Hospital. The patients were 05-60 years old. Those patients with visually significant ocular pathologies involving angle structure, cornea, retina, macular and optic nerve were excluded. Written informed consent was taken prior to procedure. A detailed history of each patient was taken about any major illness, in general, and other ophthalmic problems in particular. Detailed ophthalmic examination was carried out. Best corrected visual acuity was checked using Snellen's notation. All patients underwent Ab-externo scleral fixation of IOL.

Surgical Procedure

After preparing the patient for surgery a conjunctival peritomy was created superiorly from 3⁰clock to 9⁰clock position. Then, at the 3 and 9⁰clock positions, a partial-thickness limbal-based scleral flap that is 3mm high and 2mm wide. A 7 mm corneal scleral wound was made, and a complete anterior vitrectomy was performed. Anterior chamber and retro-pupillary space was filled with Viscoelastic. A straight needle carrying a 10-0 polypropylene suture was placed through the 09 o'clock scleral bed parallel to the iris and 0.8 mm to 2 mm posterior to the posterior surgical limbus. The needle tip was passed through the sulcus and behind the iris until it was visualized behind the pupil. In a similar manner, a 28-gauge needle was inserted through the 3 o'clock scleral bed. The barrel of the 28-gauge needle was inserted into the eye and the syringe was withdrawn from the eye (the syringe carried with it the straight needle and suture). A loop of this suture was with drawn through the corneal scleral wound. The loop of suture was cut, and securely tied one end to the superior haptic and the other to the inferior haptic. The lens was inserted into the sulcus, and rotated into position while removing slack from the attached sutures. Second 10-0 polypropylene sutures were used on a half-circle needle to take a short bite in the 3 o'clock scleral bed just anterior to the first suture's exit. The long end of the second polypropylene suture was tied to the hybrid suture; in a square knot with four throws. The same steps were followed in the 09 o'clock scleral bed. Scleral flaps were closed, and the conjunctiva re-approximated.

All patients were followed after one week and monthly for three months after the surgical procedure during each visit, best corrected visual acuity (BCVA)

was checked along with anterior segment examination using slit lamp. These findings were noted on proforma and analyzed subsequently.

Statistical analysis

All calculation were done by SPSS Version 17.0 frequencies percentages were calculated for qualitative variables like, gender, complications, visual outcome for pre and postoperative. Me-Nemar test was used to compare the difference between pre-operative best corrected visual outcome (BCVA) and postoperative (BCVA) with level of significance 0.05.

RESULTS

A total of 30 Aphakic patients without capsular support were included in this study. Average age of the patients was 34.8 years with (\pm SD = \pm 22.3 years) and rang = 6- 60 years. Out of 30 patients, 12 (40%) patients were age 10 - 34 years, 9 (30%) patients were between ages 35 - 59 years, (30%) patients were < 10 years and 2 (6.7%) patients had age > 59 years.

There were 20 (67%) male and 10 (33%) female, (Male: Female = 1: 0.5) age and sex distribution presented in (Fig. 1).

Out of 30 patients, 19 (63%) patients have history of surgery and 11 (37%) patients having the history of surgical trauma.

Post-operative visual acuity (VA) improved significantly (P-value < 0.00001) as compared to the pre-operative (Table 1).

Improvement in VA was seen in 29 (96.7%) patients (Fig. 2).

Best corrected visual acuity presented in (Table 2). Improvement was also seen in post-operative BCVA, 6/6 was observed in 1 (3.3%) patient, 6/9 was observed in 14 (46.7%) patients, 6/12 was observed in 11 (36.7%) patients while 6/18 was observed in 3 (10%) patients and only 1 (3.3%) had BCVA 6/60.

Mean \pm SD IOP was 13.7 \pm 2.2 Pre-operative and Mean \pm SD IOP was 14.5 \pm 1.8 Post-operative. Mean Difference of IOP was insignificant pre and post operatively (P-value = 0.086) (Table 3).

Astigmatism was most common post-operative complication, seen in 7 (23.3%) patients, followed by uveitis in 5 (16.7%) patients, cystoid macular edema in 3 (10%) patients, hyphema in 2 (6.7%) patients, Suture erosion in 2 (6.7%) patients and IOL decentration was seen in 1 (3.3%) patients (Table 4).

Table 1: Pre and post operative uncorrected visual acuity n = 30

Visual Acuity	Pre-Operative n (%)	Post-Operative n (%)	P-Value**
6/6 - 6/18	0	29 (96.7)	< 0.00001
1/60 -5/60	18 (60)	0	
≥ 6/60	12 (40)	1 (3.3)	

*After three months **By Sign Test

Table 2: Pre and post operative best corrected visual acuity (BCVA) n = 30

BCVA	Pre-Operative n (%)	Post-Operative n (%)
6/6	0	1 (3.3)
6/9	2 (6.7)	14 (46.7)
6/12	12 (40)	11 (36.7)
6/18	16 (53.3)	3 (10)
6/60	0	1 (3.3)

BCVA = Best Corrected Visual Acuity

Table 3: Comparison of intraocular pressure n = 30

IOP	Mean± SD	P-Value*
Pre-Operative	13.7± 2.2	0.086
Post- Operative	14.5± 1.8	

*Paired t-test

Table 4: Post operative complications n = 30

Complications	No. of Patients n (%)
Astigmatism	7 (23.3)
Uveitis	5 (16.7)
Cystoid Macular Edema	3 (10)
HypHEMA	2 (6.7)
Suture Erosion	2 (6.7)
IOL decentration	1 (3.3)

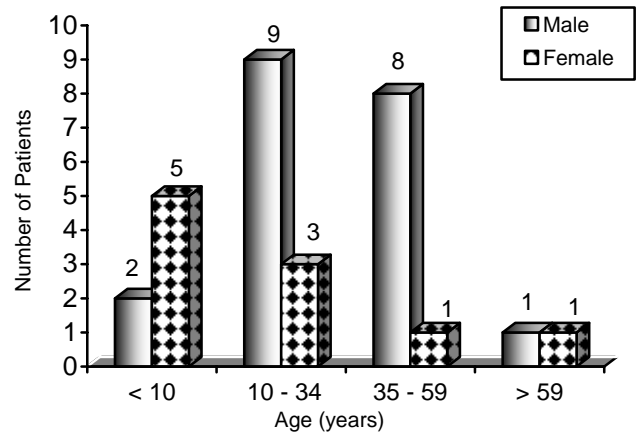


Fig. 1: Distribution of age according to gender n = 30

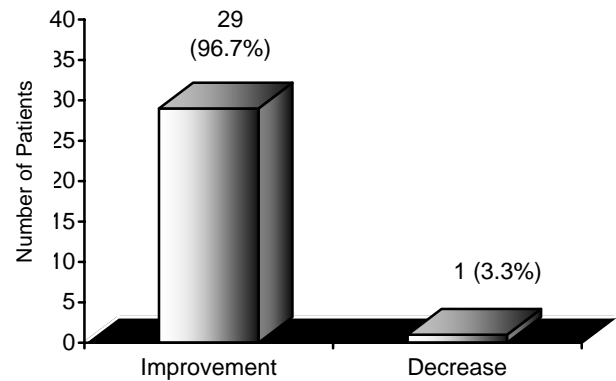


Fig. 2: Post-operative visual outcome n = 30

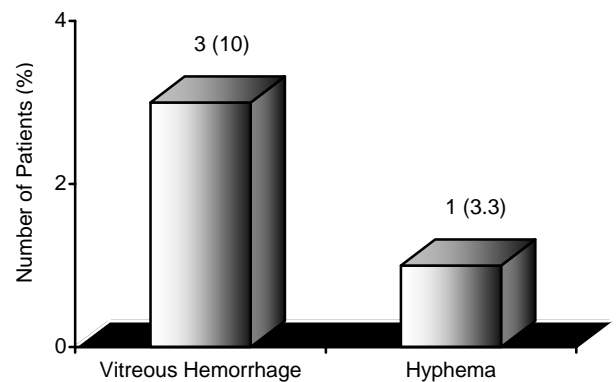


Fig. 3: Intra-operative complications n = 30

In Intra operative complications, vitreous Hemorrhage was seen in 3 (10%) patients and hypHEMA in 1 (3.3%) patients (Fig. 3).

DISCUSSION

Optical rehabilitation of patient's with monocular aphakic presents a therapeutic challenge when the

patient is unable to tolerate contact lenses for reduction of aniseikonia associated with aphakic glasses. Variable options available include, epikeratophakia, anterior chamber IOL implant, iris fixated intraocular lens and scleral fixated posterior chamber IOL implant. Among them scleral fixated PC IOL implant can provide minimum magnification of image as compared to other options.

In this study, 30 eyes of 30 patients were included. The gender distribution (67% males against 33% females) shows preponderance. The reason of this may be our rural social system where problems of female members of the family are often over looked. The mobilization of women to tertiary care units is also relatively difficult.

In this study, the post-operative best corrected visual acuity of 6/12 or better was achieved in 26 (86.7%) patients who underwent Ab-externo scleral fixation of IOL. This is comparable with Lee and Yuen¹⁴ who reported best corrected visual acuity of 6/12 or better in 19 (76%) out of 25 cases. Ghanem and colleagues¹⁵ reported postoperative BCVA of 6/9 or better in 10 (71.43%) out of 14 eyes undergoing scleral fixation of IOL. Similarly, Ozdek and co-workers¹⁶ reported the improvement of postoperative of BCVA 6/12 or better in 14 eyes (93.3%) undergoing scleral fixation of IOL.

In this study, the most common post-operative complication was astigmatism in 7 eyes (23.3%). Minimum astigmatism was - 2.00 DC and maximum was - 3.50 DC. Mean astigmatism was - 2.42 DC in this study. The cause of astigmatism was large corneal incision or tight sutures and IOL decentration. Ghanem and colleagues¹⁶ also reported astigmatism as most frequently occurring complication in 3 eyes (21.4%). Similarly, Sasahara and Kiryu¹⁷ reported astigmatism in 12 eyes (13%).

Due to iris manipulation while doing scleral fixation of IOL, we noticed anterior uveitis in 5 eyes (16.7%) which is comparable with the results of Kwong et al and Kanigowska K¹⁸.

Three eyes (10%) had postoperative BCVA of less than 6/18 the reason of that was the development of Cystoid macular edema which usually occurs due to vitreous manipulation during surgery.

There were certain limitations of this study. This study does not have an epidemiological value as incidence and prevalence of aphakic with inadequate capsular support cannot be ascertained. This is because the sampling technique was non probability

convenience. Due to the unavailability of foldable scleral fixating IOL and endoscope, we did not use them in this study.

The positive findings of this study are that the results are comparable to other studies done in different regions, proving the efficiency of procedure. The lack of serious complication makes it an effective alternate to other methods of correct in the aphakic with inadequate capsular support.

The negative findings of this study are that the outcome could be improved further by taking care of certain measures like using foldable IOL instead of rigid PMMA (polymethylmethacrylate) IOL as the former can be inserted by giving small incision as compared to later one. This will ultimately reduce the postoperative astigmatism. Similarly to insert the IOL without tilting and preventing its decentration, the haptics should be placed precisely into the ciliary sulcus that can be accomplished by using an endoscope. However learning from mistakes assures evolution and improvement.

CONCLUSION

In conclusion our results suggest that Ab-externo scleral fixation of an IOL was found to be safe and showed a favorable postoperative visual outcome in aphakic eyes.

Author's affiliation

Dr Azizur Rahman
ISRA Postgraduate Institute of Ophthalmology
Al-Ibrahim Eye Hospital, Malir,
Karachi

Dr. Israr Ahmed Bhutto
ISRA Postgraduate Institute of Ophthalmology
Al-Ibrahim Eye Hospital, Malir,
Karachi

Dr. Sadia Bukhari
ISRA Postgraduate Institute of Ophthalmology
Al-Ibrahim Eye Hospital, Malir,
Karachi

Dr. Mazharul Hassan
ISRA Postgraduate Institute of Ophthalmology
Al-Ibrahim Eye Hospital, Malir,
Karachi

DR. Muhammad Nasir Bhatti
ISRA Postgraduate Institute of Ophthalmology
Al-Ibrahim Eye Hospital, Malir,
Karachi

REFERENCE

1. **Young AL, Lenng-Gys, Cheng-LL, et al.** A modified technique of scleral fixated intra ocular lenses for aphakic correction. *Nature publishing group Eye.* 2005; 19: 19-22.
2. **Teichmann KD.** Scleral fixation of intra ocular lenses. *Saudi J Ophthalmol.* 2003; 17: 157-73.
3. **Azar DT, Clamen L, Flakier P.** Secondary intra ocular lens implantation. In: *Principles and practice of ophthalmology.* 2nd ed. Philadelphia: W.B Saunders Company. 2000; 1514-36.
4. **Tayyab AA.** Secondary Transscleral fixation of intra ocular lens implantation. *Pak J Ophthalmol.* 2004; 20: 139-42.
5. **Uthoff D, Teichmann KD.** Secondary implantation of scleral-fixated intraocular lenses. *J Cataract Refract Surg.* 1998; 24: 945-50.
6. **Mead MD, Seik-EA, Sterinert RF.** Optical rehabilitation of aphakic In: *Principles and practice of ophthalmology.* Philadelphia: W.B Saunders Company. 1994; 641-56.
7. **Lewis JS.** Ab-externo sulcus fixation. *Ophthalmic Surg.* 1991; 22: 692-5.
8. **Chakrabarti A, Gandhi RK, Chakrabarti M.** Ab-externo 4-point scleral fixation of posterior chamber intraocular lenses. *J Cataract Refract Surg.* 1999; 25: 420-6.
9. **Mittelviehhaus H, Wiek J.** A refined technique of transscleral suture fixation of posterior chamber lenses developed for cases of complicated cataract surgery with vitreous loss. *Ophthalmic Surg.* 1993; 24: 698-701.
10. **Bleckmann H, Kaczmarek U.** Functional results of posterior chamber lens implantation with scleral fixation. *J Cataract Refract Surg.* 1994; 20: 321-6.
11. **Wagoner MD, Cox TA, Ariyasu RG, et al.** Intraocular lens implantation in the absence of capsular support: a report by the American Academy of Ophthalmology. 2003; 110: 840-59.
12. **Kaynak S, Ozbek Z, Pasa E, et al.** Transscleral fixation of foldable intraocular lenses. *J Cataract Refract Surg.* 2004; 30: 854-7.
13. **Kokame GT, Yamamoto I, Mandel H.** Scleral fixation of dislocated posterior chamber intraocular lenses: Temporary haptic externalization through a clear corneal incision. *J Cataract Refract Surg.* 2004; 30: 1049-56.
14. **Lee VY, Yuen HK, Kwok AK.** Comparison of outcomes of primary and secondary implantation of scleral fixated posterior chamber intraocular lens. *Br J Ophthalmol.* 2003; 87: 1459-62.
15. **Ghanem VC, Ghanem EA, Ghanem RC, ET AL.** Monoscleral fixation IOL after extracapsular extraction of subluxated lenses in patients with Marfan syndrome. *Arq Bras Oftalmol.* 2004; 64: 763-7.
16. **Ozdek S, Sari A, Bilgihan K, Akata F, ET AL.** Surgical treatment of hereditary lens subluxations. *Ophthalmic Surg Lasers.* 2002; 33: 309-13.
17. **Sasahara M, Kiryu J, Yoshimura N.** Endoscope-assisted transscleral suture fixation to reduce the incidence of intraocular lens dislocation. *J Cataract Refract Surg.* 2005; 31: 1777-80.
18. **Kanigowska K, Gralek M, Karczmarewicz B.** [Transsclerally fixated intraocular artificial lenses in children-analysis of long-term postoperative complications]. *KlinOczna.* 2007; 109: 283-6.

Glaucoma

According to the World Health Organisation glaucoma is the leading cause of preventable irreversible blindness worldwide. Roughly 70 million of the world's population are affected by glaucoma and according to most epidemiological studies, 50 percent are undiagnosed. The incidence of glaucoma being one percent among aged 40 years and four percent in people aged 80 years. Population studies indicate that around 10 percent of patients diagnosed with glaucoma will go blind bilaterally and 20 percent will go blind unilaterally after 20 years. Pakistan has a large percentage of younger population which will be aging in next few decades requiring timely measures for adequate management of glaucoma.

M Lateef Chaudhry
Editor-in-Chief